



Hepatoprotective activity of *Anogeissus latifolia* bark in ethanol intoxicated rats

Yerra Rajeshwar^{1*}, Thota Sreekanth², Getu Kahsay¹, Dagim Ali Hussen¹, Tadele Eticha¹, Hailekiros Gebretsadik¹, Gebregziabher Girum¹



^{1,2}Pharmaceutical Chemistry and Research Unit, Department of Pharmacy, College of Health Sciences, Mekelle University, Ayder Campus, Mekelle, ETHIOPIA.

²National Institute for Science and Technology on Innovation on Neglected Diseases (INCT/IDN), Center for Technological Development in Health (CTDS), Oswaldo Cruz Foundation (Fiocruz), Av. Brasil 4036, Manguinhos, 21040-361, Rio de Janeiro RJ, BRASIL.

*Email: yerrarajeshwar@gmail.com

Abstract

Background: Herbs are known to play a vital role in the management of various liver disorders. One such herb *Anogeissus latifolia* is a plant is useful in the treatment of liver disorders. In the present study, hepatoprotective potential of *Anogeissus latifolia* was evaluated on commonly used model of experimental hepatic damage in rats.

Objective: To evaluate the hepatoprotective activity of *Anogeissus latifolia* bark against ethanol-induced hepatotoxicity in rats.

Materials & methods: Methanol extract of *Anogeissus latifolia* (MEAL) bark at the dose of 100mg and 200mg/kg, p.o. was evaluated for its efficacy in rats by inducing hepatotoxicity with ethanol (3.76mg/kg). Serum levels of GOT, GPT, ALP, direct and total bilirubin were used as biochemical markers of hepatotoxicity. Histopathological changes in the liver were also studied.

Results & Discussion: The results showed that the oral administration of MEAL resulted in a significant reduction in biochemical markers when compared with ethanol damaged rats. A comparative histopathological study of liver from test group exhibited almost normal architecture, as compared to ethanol treated group. The results are comparable to that of Silymarin. Hepatoprotective activity of MEAL exhibited better effectiveness than Silymarin in certain parameters, concluded its hepatoprotective potential.

Conclusion: Our study demonstrates the hepatoprotective activity of bark of *Anogeissus latifolia* against ethanol induced hepatotoxicity. However, further clinical studies are required to assess the safety and benefits of the plant in human beings..

Keywords: *Anogeissus latifolia*, ethanol, hepatoprotective activity, serum biomarkers.

INTRODUCTION

Liver is an important organ for detoxification and metabolism, and it has a good repairing capability. Ehanol induces a number of deleterious metabolic changes in the liver. Its excessive use for a long-time leads to development of steatosis, alcoholic hepatitis

How to Cite this Article:

Yerra Rajeshwar, Thota Sreekanth, Getu Kahsay, Dagim Ali Hussen, Tadele Eticha, Hailekiros Gebretsadik, Gebregziabher Girum (2016). Hepatoprotective activity of *Anogeissus latifolia* bark in Ethanol intoxicated rats. *The Ame J Sci & Med Res*, 2(4):11-16. doi:10.17812/ajsmr2403.

Received: 18 September 2016; Accepted 28 October 2016;
Published 12 November, 2016

and cirrhosis resulting in weight and volume changes (1). At least 80% of heavy drinkers had been reported to develop steatosis, 10-35% alcoholic hepatitis, and approximately 10% liver cirrhosis (2).

Anogeissus latifolia (Axlewood, Family: Combretaceae) is a small to medium-sized tree up to 20-30m tall with a straight and cylindrical bole up to 80-100cm in diameter; native to the India, Nepal, Myanmar, and Srilanka. It is one of the most useful trees in India. Its wide leaves (that give it the name *latifolia*) are opposite or sub-opposite, simple with grayish-yellow or whitish hairs below(3) (Figure-1). Its leaves contain large amounts of gallotannins and are used in India for tanning. The tree is the source of Indian gum, also known as ghatti gum, which is used for calicoprinting

among other uses(4). It is an important timber and the leaves and bark are used for tanning. The bark is effective in anemic conditions, urinary discharges and piles(5). According to Jain et al(6) stem bark is useful in controlling fever(7), diarrhea, dysuria, cough (8), colic, liver complaints, snakebite(9) and skin diseases.

Figure-1. *Anogeissus latifolia*



Reddy et al(10) reported tannin, (+)-leucocyanidin and ellagic acid from the bark, sapwood and heartwood, whereas Deshpande et al(11) isolated 3,3'-di-O-methyl ellagic acid-4'- β -D-xyloside and 3,4,3'-tri-O-methyl flavellagic acid-4'- β -D-glucoside from stem bark. Steroid, β -sitosterol and triterpenoid, 3- β -hydroxy-28-acetyl araxaren were isolated from the ethyl acetate fractions of stem bark of *A. latifolia*(12).

Govindarajan et al studied the wound healing(13) and antiulcer(14) potential of *A. latifolia* bark. Parvathi et al(15) evaluated the hypolipidemic potential of *A. latifolia* in albino rats. Hepatoprotective activity of *A. latifolia* against CC_4 -induced hepatotoxicity in albino rats of wistar strain was studied in Hulikere et al(16).

As no reports are available on the hepatoprotective activity of the *Anogeissus latifolia* bark in ethanol induced hepatotoxicity, we undertook the present investigation to work on ethanol induced hepatotoxicity by estimating the serum biomarkers and other appropriate possible parameters.

MATERIALS AND METHODS

Chemicals and reagents:

All the chemicals and reagents were procured commercially from Sigma Chemicals, USA; Merck, Germany; and SD Fine Chemicals, India.

Plant material and extraction:

The bark was made into small pieces and shade dried for obtaining crude extract from the plant. The dried plant material was then pulverized separately into coarse powder by a mechanical grinder. The resulting powder was extracted initially with petroleum ether and

subsequently with chloroform and methanol by hot continuous extraction method to obtain the respective extracts. The extracts were filtered and concentrated in vacuum under reduced pressure using Rotary flash evaporator. The extracts were kept in desiccator for further analysis.

Phytochemical screening:

The freshly prepared extracts (petroleum ether, chloroform, and methanol extracts) of the bark of *Anogeissus latifolia* were subjected to phytochemical screening for the detection of various constituents by using the standard methods(17&18).

Experimental induction of hepatotoxicity:

Ethanol (3.76mg/kg body weight) was dissolved in water and injected to rats by oral, for a period of 15 days.

Experimental design:

A total of 30 rats (6 normal; 24 ethanol induced hepatotoxic rats) were used in the present investigation. The animals were divided into five groups of 6 animals each (n=6) and were treated orally for 15 days(19).

Group A: served as Normal Control and received distilled water only;

Group B: received Ethanol (3.76mg/kg);

Group C: received Ethanol + MEAL (100mg/kg);

Group D: received Ethanol + MEAL (200mg/kg); and

Group E: received Ethanol + Silymarin (100mg/kg).

The effect of MEAL on ethanol induced hepatotoxic rats were determined by measuring the physical parameters (such as liver weight and volume), biomarker enzymes, and histopathology.

Measurement of liver weight and liver volume:

Livers from all animals were excised, washed with ice-cold saline, weighed and measured the wet liver volume(20).

Assessment of biomarker enzymes:

After the drug treatment, ie., on day 16, all the animals were sacrificed under light ether anesthesia 24 hours after the last dose. Blood was collected by puncturing the retro orbital plexus and was allowed to clot for 45 min at room temperature. The serum was collected by centrifugation (Remi, Mumbai, India) at 3000 rpm for 15 min, and used for the estimation of various biochemical parameters such as serum glutamate oxaloacetate transferase (SGOT)(21), serum glutamate pyruvate transferase (SGPT)(21), serum alkaline phosphatase (SALP)(22), direct bilirubin (23), and total bilirubin (23).

Histopathology:

The liver samples were excised from the experimental animals of each group and washed with normal saline. Initially the materials were fixed with 10% buffered neutral formaline for 48 hrs and then with

bovine solution for 6 hrs. They were then processed for paraffin embedding. The sections were taken at 5mm thickness using microtome, processed in alcohol-xylene series and stained with alum-hemotoxylin and eosin (24). The sections were examined microscopically for the evaluation of histopathological changes.

Statistical analysis:

The experimental results were expressed as the mean±S.E.M. Data were assessed by the method of analysis of ANOVA followed by Student's *t*-test. P value of < 0.05 was considered as statistically significant.

RESULTS & DISCUSSION

Liver is one of the important organs of the body hence damage to the liver leads to severe pathological problems or to the end of life. The liver can be injured by many chemicals and drugs(25).

Phytochemical screening:

The phytochemical screening of the extracts of *Anogeissus latifolia* bark showed that the crude extracts of Petroleum ether, chloroform, and methanol were found to contain small quantities of carbohydrates, alkaloids, fixed oils and fats, glycosides, triterpenoids, tannins, flavones and flavonoids (Table-1).

Evaluation of Hepatoprotective activity:

Effect of MEAL on liver weight and liver volume

It is reported that liver mass and volume are important parameters in ascertaining the hepatoprotective effect of the drugs. Water is retained in the cytoplasm of hepatocytes leading to enlargement of liver cells, resulting in increased total liver mass and volume(26). Ethanol treatment in rats resulted in enlargement of liver was evident by increase in the wet liver weight and volume. The groups treated with Silymarin and MEAL bark (100mg and 200mg/kg) showed significant (P<0.05) restoration of wet liver weight and wet liver volume nearer to normal. The results are shown in Table-2.

Effect of MEAL on biomarker enzymes in ethanol induced hepatotoxic rats

Hepatotoxic (ie., ethanol) gets converted into radicals in liver by the action of enzymes and these attack the unsaturated fatty acids of membranes in presence of oxygen to give lipid peroxides consequently. The functional integrity of hepatic mitochondria is altered, leading to liver damage. During hepatic damage, cellular enzyme like SGOT, SGPT, SALP and serum bilirubin present in the liver cell, leak into the serum resulting to increase in concentration(27).

Table-1. Preliminary phytochemical screening of *Anogeissus latifolia* bark

| Sl. No. | Phytoconstituents | Pet ether extract | Chloroform extract | Methanol extract |
|---------|--------------------------|-------------------|--------------------|------------------|
| 1 | Carbohydrates | - | - | + |
| 2 | Proteins and amino acids | - | - | - |
| 3 | Alkaloids | - | + | + |
| 4 | Fixed oils and fats | + | - | - |
| 5 | Glycosides | - | + | + |
| 6 | Triterpenoids | + | - | - |
| 7 | Phenolics and tannins | - | - | - |
| 8 | Saponins | - | + | + |
| 9 | Flavones and flavonoids | - | + | + |

where, + = present; - = absent

Table-2. Effect of MEAL on wet liver weight and wet liver volume

| Group | Treatment (Dose) | Wet liver weight (g/100g) | Liver volume (ml/100g) |
|-------|--------------------------------|---------------------------|--------------------------|
| A | Normal control (10ml/kg) | 2.35 ± 0.35 | 2.35 ± 0.35 |
| B | Ethanol control (3.76mg/kg) | 4.43 ± 0.59 [#] | 4.91 ± 0.40 [#] |
| C | Ethanol + MEAL (100mg/kg) | 2.37 ± 0.21 [*] | 2.79 ± 0.70 [*] |
| D | Ethanol + MEAL (200mg/kg) | 2.63 ± 0.72 [*] | 2.77 ± 0.11 [*] |
| E | Ethanol + Silymarin (100mg/kg) | 2.16 ± 0.11 [*] | 2.87 ± 0.32 [*] |

Values are mean ± SEM (n=6) one way ANOVA.

where, [#] represents significant at P<0.01, compared to Normal control;

^{*} represents significant at P<0.05, compared to Ethanol control.

Liver toxicity elevated the SGOT levels in serum due to the damage to the tissues producing acute necrosis, such as severe viral hepatitis and acute cholestasis. Alcohol damage and cirrhosis can also associate with mild to moderate elevation of transaminases. Serum levels of SGPT can increase due to damage of the tissues producing acute hepatic necrosis, such as viral hepatitis and acute cholestasis. Alcoholic liver damage and cirrhosis also can associate with mild to moderate elevation of transaminases(28&29). In case of toxic liver, SALP levels are very high, which may be due to defective hepatic excretion or by increased production of SALP by hepatic parenchymal or duct cells(29).

In the present investigation, significantly elevated levels of SGOT, SGPT, SALP, serum direct and total bilirubin were observed in ethanol induced group. Administration of MEAL significantly ($P<0.05$, at the dose of 100mg and 200mg/kg) decreased the increased

levels of biomarker enzymes of the liver to the normal levels in a dose dependent manner (**Table-3**).

Histopathological observation:

Histopathological study of liver in normal control showed normal hepatic cells. In ethanol induced group, severe toxicity was evidenced by profound central lobular fatty degeneration, focal necrosis and vacuolization. MEAL at the dose of 200mg/kg, the liver exhibited a typical lobular arrangement, few hepatic cells show fat accumulation, represents moderate protection in ethanol induced liver damage. Silymarin at the dose of 100mg/kg showed significant protection to considerable extent as evident from the formation of normal hepatocytes and their lobular architecture was normal (Figure 2(i) to 2(v)).

Table-3. Effect of MEAL on SGOT, SGPT, SALP, Direct and Total bilirubin levels

| Treatment | SGOT (U/L) | SGPT (U/L) | SALP (ml/100g) | Direct bilirubin (mg/dl) | Total bilirubin (mg/dl) |
|----------------------------|--------------|-------------|----------------|--------------------------|-------------------------|
| Normal control | 34.90±1.50 | 29.35±0.90 | 28.15±0.14 | 0.18±0.01 | 0.20±0.01 |
| Ethanol control | 177.95±1.35 | 123.90±1.50 | 81.24±1.38 | 0.86±0.03 | 1.39±0.09 |
| Ethanol + MEAL (100mg/kg.) | 112.56±0.75* | 85.6±0.55* | 64.00±2.05* | 0.65±0.02* | 1.08±0.07 |
| Ethanol + MEAL (200mg/kg.) | 102.30±0.60* | 72.4±0.05# | 38.60±0.97@ | 0.43±0.02# | 0.71±0.05# |
| Ethanol + Silymarin | 86.86±0.70@ | 50.75±0.05@ | 30.80±2.05@ | 0.33±0.01@ | 0.45±0.05@ |

Values are mean ± SEM (n=6) one way ANOVA.

Where, *represents significant at $p<0.05$, #represents highly significant at $p<0.01$, and @represents very significant at $p<0.001$. All p values are compared with toxicant.

Figure-2. Histopathological study of treated livers

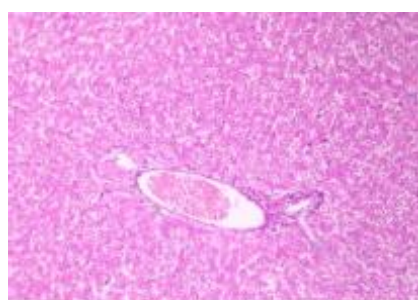


Figure-2(i). Normal control

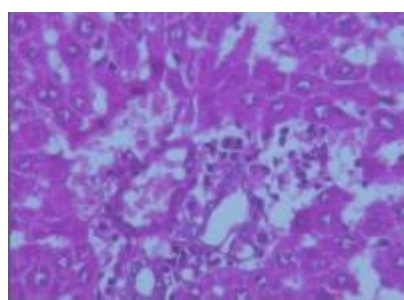


Figure-2(ii). Ethanol control

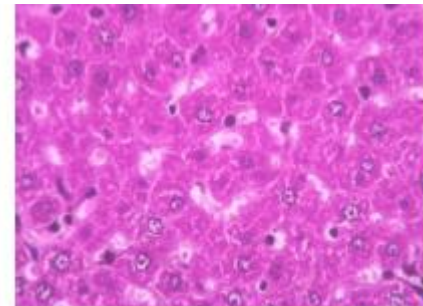
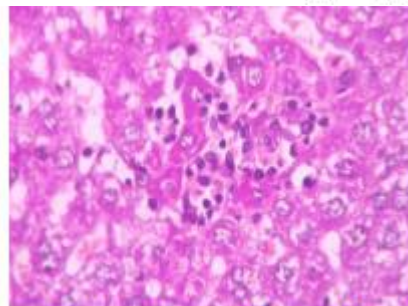
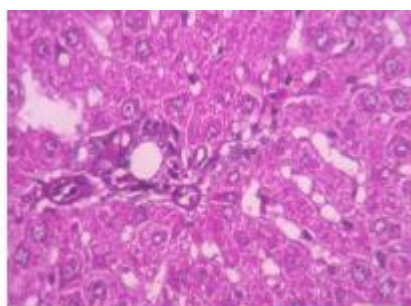


Figure-2(iii). Ethanol + MEAL (100mg/kg) Figure-2(iv). Ethanol + MEAL (200mg/kg) Figure-2(v). Ethanol + Silymarin (100mg/kg)

Conclusion

From the findings, it can be concluded that methanol extract of *Anogeissus latifolia* has significant hepatoprotective effect against ethanol induced hepatotoxicity in rats, which may be via non-specific mechanisms. However, extensive studies are needed to evaluate the precise mechanism(s), active principle(s), and the safe profile of the plant as a medicinal remedy for hepatotoxicity disorders.

Competing interests

The authors have declared that no competing interests exist.

References

- Kumar V, Abbas A, and Fausto N. Robins and Cotran Pathologic Basis of Disease. 7th ed. Philadelphia: W.B.Saunders; 2003.
- Saravanan N, and Nalini N. Antioxidant effect of *Hemidesmus indicus* on ethanol induced hepatotoxicity in rats. *Journal of Medicinal Food*. 2007; 10(4): 675-682.
- Orwa C, Mutua A, Kindt R, Jamnadass R, and Anthony S. Agroforestry Database: a tree reference and selection guide version 4.0. World Agroforestry Centre, Kenya, 2009.
- Reddy KK, Rajadurai S, Sastry KNS, and Nayudamma Y. Studies on dhava tannins. I. The isolation and constitution of a gallotannin from dhava (*Anogeissus latifolia*). *Australian Journal of Chemistry*. 17(2): 238-245.
- Kirtikar KR, and Basu BD. Indian medicinal Plants. Jayad Press, Delhi. 1975; Vol 2: 236.
- Jain SK. Dictionary of Indian folk Medicine and Ethnobotany. Deep Publication, New Delhi. 1991; 225.
- Nag A, Galav P, and Ketava SS. Indigenous animal health practices from the Udaipur District, Rajasthan. *Indian Journal of Traditional Knowledge*. 2007; 6(4): 583-588.
- Patil MV. Ethnobotany of Nashik District. 2006; 54.
- Venkata Ratan K, Venkata Raju RR. Folk remedies for insect bite from Gundlabrahmeswaram wild life sanctuary. Andhra Pradesh. *Indian Journal of Traditional Knowledge*. 2008; 7(3): 436-437.
- Reddy KK, Rajadurai S, and Nayadamma Y. Studies on Dhava (*Anogeissus latifolia*) tannins: Part III - polyphenols of bark, sapwood and heartwood of Dhava. *Indian Journal of Chemistry*. 1965; 3: 308-310.
- Deshpande VH, Patil AD, Rama Rao AV, and Venkataraman K. 3,3'-Di-O-methyl ellagic acid-4'-b-D-xyloside and 3,4,3'-tri-O-methylflavellagic acid-4'-b-D-glucoside from the *Anogeissus latifolia* bark. *Indian Journal of Chemistry*. 1976; 14B: 641-643.
- Rehman MS, Rahman MZAB, and Ahad Uddin M. Steroid and Triterpenoid from *Anogeissus latifolia*. *Dhaka University Journal of Pharmaceutical Sciences*. 2007; 6(1): 47-50.
- Govindrajan R, Vijayakumar M, Rao CV, Shirwaikar A, Mehrotra S, Pushpangadan P. Healing potential of *Anogeissus latifolia* for dermal wounds in rats. *Acta Pharmaceutica*. 2004; 54(4): 331-338.
- Govindrajan R, Vijaykumar M, Singh M, Rao CV, Shirwaikar A, Rawat AKS, and Pushpangadan P. Antiulcer and antimicrobial activity of *Anogeissus latifolia*. *Journal of Ethnopharmacology*. 2006; 106(1): 57-61.
- Parvathi KMM, Ramesh CK, Krishna V, Paramesha M, and Kuppasi IJ. Hypolipidemic activity of gum ghatti of *Anogeissus latifolia*. *Pharmacognosy Magazine*. 2009; 5(19): 11-14.
- Ananth Pradeep H, Khan S, Ravikumar K, Fazil Ahmed M, Srinivasa Rao M, Kiranmai M, Sudhershana Reddy D, Rasheed Ahmed S, and Ibrahim M. Hepatoprotective evaluation of *Anogeissus latifolia*: *In vitro* and *in vivo* studies. *World Journal of Gastroenterology*. 2009; 15(38): 4816-4822.
- Trease GE, and Evans WC. In: Pharmacognosy. 13th ed. ELBS Publication, Delhi. 1989; 171.
- Harbone JB. Phytochemical methods. A Guide to Modern Techniques of Plant Analysis. 2ed. Chapman and Hall, London, 1984; 84-274.
- Mazumder UK, Gupta M, Rajeshwar Y, Roy R, Banerjee P, and Banerjee A. Antihepatotoxic effects and *in vivo* antioxidant activity of *Mucuna pruriens* (Fabaceae) against Acetaminophen induced liver damage in rats. *Transactions: The National Institute of Science*. 2006; 42: 59-65.
- Ghosh T, Maity TK, Das M, Bose A, and Dash GK. Hepatoprotective activity of *Bacopa monnieri* L against ethanol-induced hepatotoxicity in rat. *Phcog. Net*. 2007; 3(10): 95-100.
- Bergmeyer HU, Scheibe P, and Wahlefeld AW. Optimization of methods for aspartate aminotransferase and alanine aminotransferase. *Clinical Chemistry*. 1978; 24(1): 58-61.
- King J. The hydrolases-acid and alkaline phosphatase. In: Van E, editor. Practical Clinical Enzymology. London, Nostrand Company Ltd. 1965; 191-208.
- Malloy HT, and Evelyn KA. The determination of bilirubin with the photoelectric colorimeter. *Journal of Biological Chemistry*. 1937; 119: 481-490.
- Galigher and Koyloff. Manual of Practical Pathology. Vol III. 1971; 82: 70-77.
- Leo MA, Arai M, Sato M, and Lieber CS. Hepatotoxicity of vitamin A and ethanol in the rat. *Gastroenterology*. 1982; 82: 194-205.
- Reddy KK, Rajadurai S, Nayadamma Y. Dhava (*Anogeissus latifolia*) tannins. *Australian Journal of Chemistry*. 1964; 17(2): 238-245.
- Deb AC. Fundamentals of Biochemistry. 7th Ed. New Central Book Agency: Kolkata, 1998.

28. Zimmerman HJ, and Seeff LB. Enzymes in hepatic disease. In Goodly EI editor. Diagnostic enzymology. *Medical Clinics of North America*. 1959; 43(2): 371-400.
29. Sergent O, Pereira M, Belhomme C, Chevanne M, Huc L, and Lagadic-Gossmann D. Role for membrane fluidity in ethanol-induced oxidative stress of primary rat hepatocytes. *The Journal of Pharmacology and Experimental Therapeutics*. 2005; 313: 104-111.
